

Preventing unrecognised oesophageal intubation

Prof Paul Baker

Professor, University of Auckland

Reprinted with thanks and permission from the NZSA reference:

Dr P A Baker, New Zealand Anaesthesia Magazine, NZSA, p 16-18, December 2022.

Introduction

Every year, patients die from unrecognised oesophageal intubation. This rare, lethal complication of airway management can occur to any patient of any age undergoing tracheal intubation. It can also involve any airway practitioner of any seniority or previous experience. This complication is usually an avoidable occurrence resulting from human error. Recent deaths internationally from unrecognised oesophageal intubation have heightened concern about this problem and resulted in a new consensus guideline from the Project for Universal Management of Airways (PUMA) and international airway societies, which has been endorsed by the New Zealand Society of Anaesthetists. In this article, the key recommendations from the PUMA document will be presented and discussed (Fig 1).¹

Key recommendations

These key recommendations arise after reading many cases of unrecognised oesophageal intubation. Certain important issues and recurrent themes occur which will be discussed in this article.












Preventing unrecognised oesophageal intubation: A consensus guideline from the Project for Universal Management of Airways and international Airway Societies	
	Always monitor exhaled CO ₂ & SpO ₂ during airway management
	Routinely use a videolaryngoscope whenever feasible
	The airway operator should verbalise the view at laryngoscopy
	Following intubation, the airway operator & assistant should each verbalise whether sustained exhaled CO ₂ & adequate SpO ₂ are present
	Inability to detect sustained exhaled CO ₂ requires oesophageal intubation to be actively excluded
	The default response to failure to satisfy the criteria for sustained exhaled CO ₂ should be to remove the tube and attempt ventilation using a facemask or supraglottic airway
	If tube is not immediately removed, repeat laryngoscopy, flexible bronchoscopy, ultrasound or an oesophageal detector device are all valid alternative techniques for excluding oesophageal intubation
	Clinical examination should not be used to exclude oesophageal intubation
	The tube should be removed if oesophageal placement can't be excluded, sustained exhaled CO ₂ can't be restored or SpO ₂ deteriorates before sustained exhaled CO ₂ is restored
	Actions should be taken to standardise & improve the distinctiveness of variables on monitor displays
	Interprofessional education programmes addressing technical & team aspects of task performance should be undertaken to implement these guidelines

Fig 1.

Monitoring

Waveform capnography is the “gold standard” technique to detect and monitor expired CO₂ and therefore identify the absence of expired CO₂ after oesophageal intubation.² It is the most reliable method to confirm and monitor tracheal tube placement even in low perfusion states, including cardiac arrest, with sensitivity and specificity rates of 100%.³

Various problems occur with capnography, including lack of availability in all areas where airway management takes place, failure to check the capnograph after tracheal intubation, misinterpretation of an absent waveform, lack of knowledge about the significance of variations of waveforms and confusion between capnography and other waveforms on a monitor (Fig 2). Each of these issues should be addressed with education and reflected in our ANZCA practice guidelines. There is also the need for willingness by practitioners to modify their own practices and adopt relatively simple measures outlined in the key recommendations described earlier (see Fig 1).

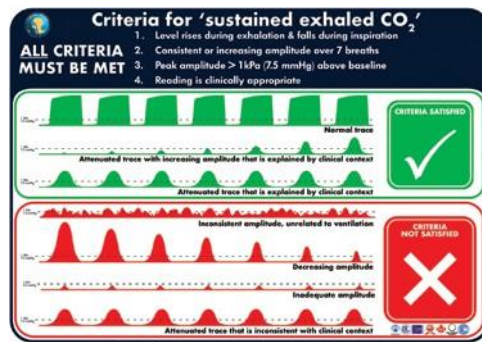


Fig 2. Criteria for 'sustained exhaled carbon dioxide'. This graphic has been designed to be used as both a foundation tool to be reviewed in advance of clinical use and an implementation tool to be referred to in real time during clinical practice [93]. A high-resolution version of this graphic is available for download at <https://www.UniversalAirway.org/downloads>. Printing and laminating this at A3 size is recommended.

Early identification of an oesophageal intubation with capnography is essential to avoid severe patient morbidity or mortality. Using clinical signs of tracheal intubation including tube misting, chest movement and breath sounds on auscultation to exclude oesophageal intubation is unreliable and can result in delays in correct patient management. While clinical examination may be used to encourage removal of a tube, it should never be used to discourage it.

Pulse oximetry is not a replacement for capnography, but it is a useful adjunct for early diagnosis and monitoring the likelihood of an oesophageal intubation. Comparison of oxygen saturation before and after tracheal intubation in conjunction with capnography findings may accelerate correct diagnosis of oesophageal intubation. Conversely, reliability of sustained normal oxygen saturations can lead to false confidence, particularly after preoxygenation and other apnoeic oxygenation techniques, leading to delays in the management of an oesophageal intubation.

Flexible bronchoscopy is a helpful technique to confirm correct tracheal tube placement, particularly when there is concern about safe extubation in the face of a possible oesophageal intubation. Ultrasound has also been shown to be reliable for oesophageal intubation diagnosis, but these techniques can take time to implement and do not function for ongoing monitoring. In the absence of other more reliable monitoring, the oesophageal bulb will help identify tracheal versus oesophageal intubation using negative pressure from the deflated bulb to inflate in the trachea and not in the oesophagus (Fig 3)

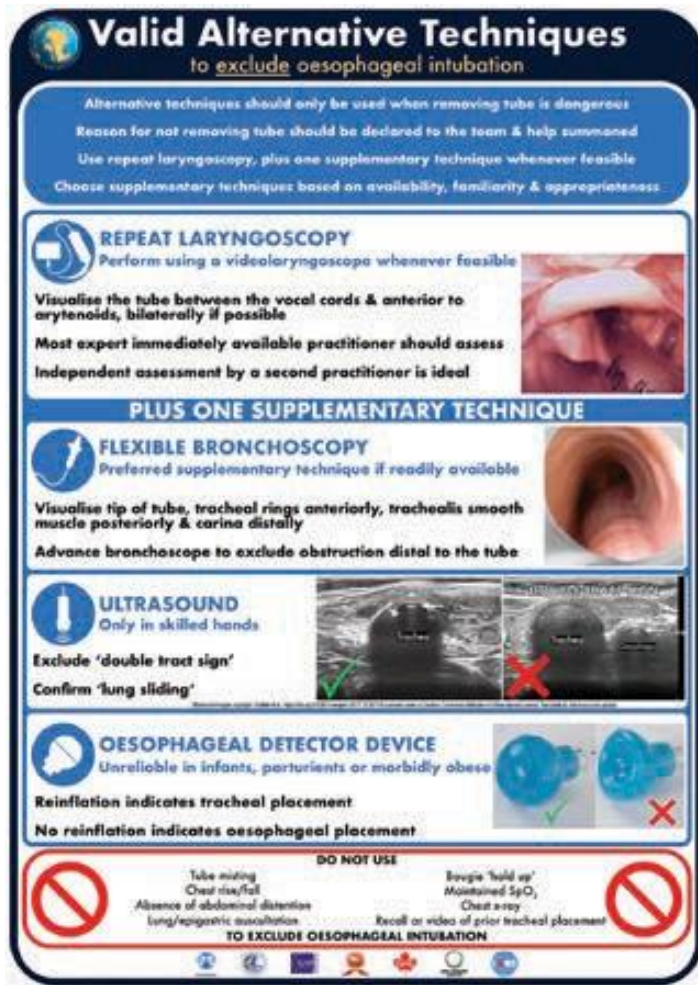


Fig 3. Algorithm for approaching failure to satisfy the criteria for 'sustained exhaled carbon dioxide' following passage of a tracheal tube. This algorithm has been designed to be used as an implementation tool [93], to be referred to in real time during clinical practice. Optimal use during clinical practice requires prior familiarity with the algorithm and guideline text. A high resolution version of the algorithm is available for download at <https://www.UniversalAirway.org/downloads>. Printing and laminating this at A3 size is recommended.

Tracheal intubation

The goal of tracheal intubation is to safely deliver an endotracheal tube into the trachea without causing hypoxia or trauma. The ideal technique involves slow sequential exposure of anatomy using an intubation device and oxygen. This technique is designed to correctly identify the glottis and avoid bypassing the airway on the way to the oesophagus, thereby mistaking the oesophagus for the glottis (glottic impersonation). (Fig 4). A range of intubation devices can be used to achieve this goal, but evidence suggests a videolaryngoscope reduces the risk of oesophageal intubation, improves the view of the glottis compared to direct laryngoscopy, and facilitates a shared view of the glottis which, combined with a verbal description of the laryngeal view, adds to the safety of the procedure.⁴ The latest practice guideline recommends routine use of a videolaryngoscope whenever feasible. Where not currently feasible this recommendation should be considered aspirational.¹

Not all intubations take place under ideal conditions, and multiple factors can contribute to a poor view of the glottis leading to an oesophageal intubation, particularly after a repeat laryngoscopy attempt. These factors can include poor preparation, inexperience,

poor equipment, adverse patient anatomy and physiology, stressful conditions and distractions. Many of these factors can be improved if time is taken to optimise the intubation attempt.

Identification of correct tracheal intubation is a critical step, worthy of a few dedicated seconds, to confirm correct placement, with a witness, and to identify a sequence of capnography waveforms which meet the criteria for 'sustained exhaled carbon dioxide'. (see Fig 2)

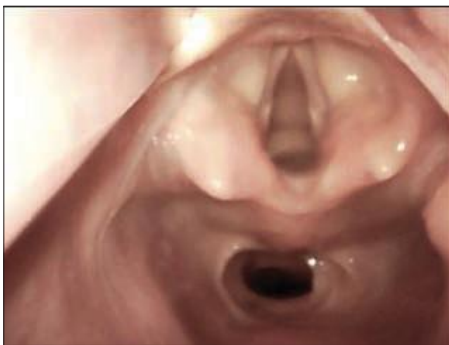

Fig 4. This image taken from a cadaver shows a view of a larynx with the oesophagus below. The oesophagus has a blanched lateral boarder appearing like an aryepiglottic fold and arytenoid plus an anterior boarder appearing like an epiglottis. Deep positioning of a laryngoscope blade could lead to an oesophageal intubation. (Image courtesy of Professor George Kovacs)

Human factors

When reviewing unrecognised oesophageal intubation reports, numerous examples appear involving errors of judgement, including confirmation bias of alternative diagnoses such as bronchospasm.¹ Other problems include fixation error, overconfidence by airway practitioners, or denial of oesophageal intubation.⁵ These problems may be aggravated by a range of other adverse human factor behaviours, including poor team communication and hierarchy issues and making bystanders reluctant to speak up.⁶ Refusal to check the tracheal tube by the primary practitioner has been reported, leading to critical delays in correct diagnosis and fatal consequences.⁵

To avoid distraction or denial of oesophageal intubation during this critical phase of airway management, a safety step involving a mini 'timeout' is recommended (see Fig 2). This pause should only take a few seconds, drawing attention to the capnograph immediately after every tracheal intubation, and take precedence over other activities that can be distracting.⁹ After that, if the criteria for 'sustained exhaled carbon dioxide' are not met, remove the tube, and rely on oxygenation via a supraglottic device or face mask. If removing the tube is considered potentially dangerous and capnography is equivocal, the position of the tube can be confirmed by witnessed repeat (ideally video) laryngoscopy, in combination with flexible bronchoscopy, ultrasonography or use of an oesophageal detector device whenever feasible. (see Fig 3)¹

Conclusion

With the benefit of education, monitoring and a willingness to modify clinical practice,

“oesophageal intubation” can be recognised and managed safely. Adoption of the recommendations outlined in this guideline has the potential to save lives.

Acknowledgement

I thank and acknowledge Dr Nick Chrimes who reviewed this paper and Professor George Kovacs who provided the image seen in Figure 4 from the Dalhousie University’s Human Body Donation Program. Used with permission.

